

From chronicity to healing using HydroClean®: Advancing wound care through the Wound Balance concept

This article is the first in a series that explores the early intervention and treatment of chronic and acute wounds through the Wound Balance concept and use of non-medicated wound dressings (NMWDs), including HydroClean®/HydroClean® Advance and Zetuvit Plus Silicone Border/ RespoSorb® Silicone Border. These dressings work in concert to optimise the wound microenvironment. Early intervention in wound chronicity involves identifying barriers to healing and implementing the Wound Balance concept to restore a normal healing trajectory. This shift from a chronic to an acute wound healing environment is supported by the action of hydro-responsive wound dressings (HRWDs) such as HydroClean®/HydroClean® Advance. The clinical cases presented in this article illustrate the effectiveness of HydroClean® in wound bed preparation (WBP), infection management and moisture balance.

Dr Saqer Al-Mualla

Consultant Plastic Surgeon, Head of Plastic Surgery Department; Deputy CEO, Al Qassimi Hospital, Sharjah, United Arab Emirates

Dr Salma Saeed

Wound Specialist, Hyperbaric Physician, Al Qassimi Hospital, Sharjah, United Arab Emirates

Dr Noura Salim

Specialist Plastic, Reconstructive Surgery, Wound Specialist; Head of Regenerative Center, Al Qassimi Hospital, Sharjah, United Arab Emirates

From chronicity to healing using HydroClean®: Advancing wound care through the Wound Balance concept

This article is the first in a series that explores the early intervention and treatment of chronic and acute wounds through the Wound Balance concept and use of non-medicated wound dressings (NMWDs), including HydroClean®/HydroClean® Advance and Zetuvit Plus Silicone Border/ RespoSorb® Silicone Border. These dressings work in concert to optimise the wound microenvironment. Early intervention in wound chronicity involves identifying barriers to healing and implementing the Wound Balance concept to restore a normal healing trajectory. This shift from a chronic to an acute wound healing environment is supported by the action of hydro-responsive wound dressings (HRWDs) such as HydroClean®/HydroClean® Advance. The clinical cases presented in this article illustrate the effectiveness of HydroClean® in wound bed preparation (WBP), infection management and moisture balance.

Chronic, hard-to-heal wounds are a significant global public health concern, placing a burden on patients, healthcare professionals, and healthcare systems. It is estimated that in developed countries, 1–2% of the population is affected by chronic wounds at any given time (Olsson et al, 2019). These wounds often require frequent healthcare visits and extended periods of hospitalisation, contributing to increased financial strain on patients and healthcare systems. Additionally, they negatively impact the quality of life of individuals and their families, affecting both physical and emotional wellbeing (International Wound Infection Institute, 2022). Therefore, it is crucial that these barriers to healing are identified and addressed early to optimise the healing process and avoid long-term chronicity (Wounds International, 2023).

What is Wound Balance?

The Wound Balance concept identifies three key factors that must be ‘balanced’ to optimise the wound microenvironment and facilitate wound healing [Figure 1; Wounds International, 2023]. These factors encompass several potential barriers to wound healing.

- **Wound Care:** Focuses on managing wound biomarkers, exudate levels, moisture balance and recognising early signs of chronicity
- **Patient Care:** Involves individualised patient care, considering the patient’s quality of life, engagement with treatment and clinical goals
- **Clinical Care:** Ensures consistency in clinical

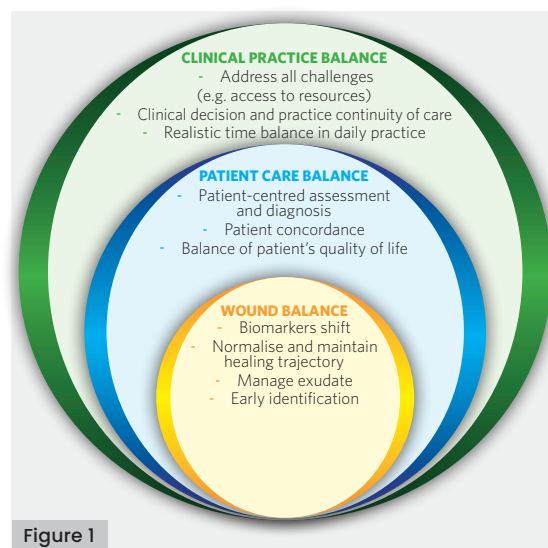


Figure 1

decision-making while addressing logistical challenges such as resource availability and time management.

Barriers to healing within wound care, which result in the prolonged nature of chronic wounds, include the presence of:

- Non-viable tissue
- Infection/inflammation
- Excessive protease levels – e.g. matrix metalloproteinases (MMPs; particularly MMP-2 and MMP-9) and polymorphonuclear granulocytes elastase
- Growth factor inactivation and matrix destruction
- Aberrant local inflammation – e.g. M1/M2-dominated inflammation, oxidative stress

Dr Saqer Al-Mualla

Consultant Plastic Surgeon, Head of Plastic Surgery Department; Deputy CEO, Al Qassimi Hospital, Sharjah, United Arab Emirates

Dr Salma Saeed

Wound Specialist, Hyperbaric Physician, Al Qassimi Hospital, Sharjah, United Arab Emirates

Dr Noura Salim

Specialist Plastic, Reconstructive Surgery, Wound Specialist; Head of Regenerative Center, Al Qassimi Hospital, Sharjah, United Arab Emirates

Key words

- Chronic wounds
- Hydroclean®
- Hydro-responsive wound dressings
- Non-medicated wound dressings
- Wound balance

Figure 1: The Wound Balance concept (Wounds International, 2023)

Declarations

Unrestricted medical writing draft support was funded by HARTMANN.

- Unbalanced moisture levels (Sterpione et al, 2021; Goedecke et al, 2022)
- Nutrient/oxygen deficiency.

Balancing the wound environment is key to optimising the patient's healing potential. This can be achieved through interventions like WBP in alignment with the TIMERS framework (Atkin et al, 2019), with consideration to the removal of non-viable tissue (debridement), management of infection, exudate control, and promotion of a moist wound healing environment. These actions help achieve a healthy granulating wound bed and promote re-epithelialisation (Schultz et al, 2003; Dowsett and Ayello, 2004; Atkin et al, 2019; Dowsett and Hall, 2019; Moore et al, 2019).

Infection management and non-medicated wound dressings (NMWDs)

NMWDs play an important role in managing wound infections and supporting antimicrobial stewardship, an essential strategy to prevent the global rise of antimicrobial resistance. According to the Interagency Coordinating Group on Antimicrobial Resistance (2019), without effective intervention, antimicrobial resistance could result in up to 10 million deaths annually and impose an economic burden of approximately £66 trillion by 2050.

NMWDs are dressings that contain no active or pharmaceutical agents but reduce bacterial load through alternative methods, such as physical methods (World Union of Wound Healing Societies [WUWHS], 2020). These dressings can be used to manage excessive inflammation, wound infection and biofilm, while also reducing bioburden. This helps maintain Wound Balance and prevent bacterial proliferation without selecting antimicrobial-resistant organisms. By supporting antimicrobial stewardship programmes, NMWDs help prevent the misuse and overuse of medicated treatments, preserving their effectiveness and mitigating the risk of antimicrobial resistance (WUWHS, 2020; Rippon et al, 2021).

Examples of NMWDs include (but are not limited to; WUWHS, 2020):

- Hydro-responsive wound dressings (HRWDs) – e.g. HydroClean®/HydroClean® Advance (PAUL HARTMANN AG, Germany)
- Superabsorbent polymers (SAP)
- Hydrogels
- Hydrocolloids
- DACC-coated dressings
- Carboxymethylcellulose (CMC) dressings.

Hydro-responsive wound dressings (HRWDs)

HydroClean®/HydroClean® Advance is a non-medicated HRWD. This means that it can deliver or absorb moisture as required, depending

on the wound environment, without the use of any active antimicrobial agents. Instead, it promotes wound cleansing and autolytic debridement (WUWHS, 2020; Ousey et al, 2016a; Sterpione et al, 2021) through a soft and conformable pad with a superabsorbent polyacrylate core pre-activated with Ringer's solution (Ousey et al, 2016b; WUWHS, 2020). On application, the dressing immediately releases Ringer's solution to hydrate the underlying tissue, soften and detach devitalised tissue, while simultaneously absorbing wound exudate. This dual action helps sequester potentially harmful proteins (e.g. MMPs and neutrophil elastase) and bacteria, trapping them within the dressing core and away from the wound surface (WUWHS, 2020; Goedecke et al, 2022).

HydroClean® has been used in multiple clinical studies to enable wound cleansing and debridement (Atkin and Ousey, 2016; Rogers and Rippon, 2017; Sterpione et al, 2021; Goedecke et al, 2022). It has also been shown to reduce excess proteases in the wound bed, minimising localised tissue damage and promoting healthy granulation tissue formation (Humbert et al, 2014; Mikosinski et al, 2022).

The mechanism of action of HydroClean®/HydroClean® Advance [Figure 2] aligns with the first three stages of the TIMERS framework:

- T:** Tissue debridement and removal of sloughy and necrotic tissue via autolytic debridement
- I:** Infection control by maintaining a low bioburden through the absorption, sequestration and retention of microorganisms
- M:** Moisture balance via the release of Ringer's solution and absorption of wound exudate.

Clinical case studies

The following cases demonstrate the use of HydroClean®/HydroClean® Advance in managing various wound types. These case studies highlight the dressing's effectiveness in promoting wound healing, controlling infection and facilitating autolytic debridement in clinical practice. Patient consent has been received for the publication of all images.

Case 1. Necrotic wound with exposed bone following open fracture

Patient presentation and history

A 31-year-old male presented to the emergency department with severe pain, difficulty walking and significant swelling in his left leg, ankle and foot. He was previously healthy with no known chronic comorbidities but had sustained an injury to his left leg two weeks prior after falling from a bicycle. The patient had delayed seeking

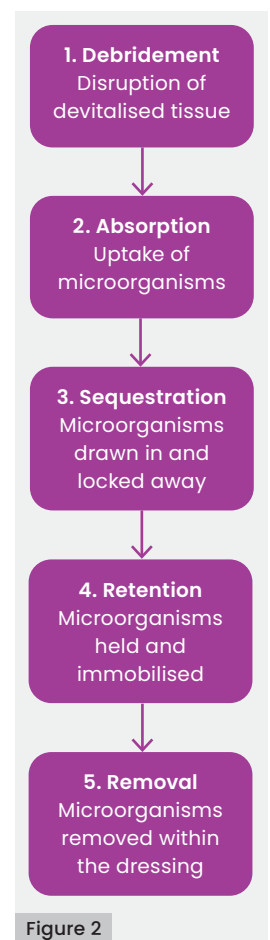


Figure 2

Figure 2. Mechanism of action of HydroClean®/HydroClean® Advance

medical care and initially used home remedies, including the application of topical liniments and bamboo sticks wrapped around the leg. This approach resulted in immobility, leaving him bedridden for two weeks before he sought medical attention.

On arrival, the patient received treatment for the open fracture, which included realignment of the bones. Orthopaedic examination revealed significant muscle wasting in the left leg, particularly in the quadriceps. Multiple skin ulcers and excoriations were observed over the distal third of the tibia and around the left ankle. There was noticeable deformity and tenderness with abnormal mobility in the mid-shaft of the tibia and fibula. However, distal neurovascular status was reported as adequate. Due to signs of infection, oral antibiotic therapy (Co-Amoxiclav 1g twice daily for two weeks) was initiated. The patient was subsequently referred to the wound care department for further management.

Wound assessment

The wound care team identified an open wound at the site of the open fracture on the anterior aspect of the left leg, measuring 7cm (length) x 3cm (width) x 1cm (depth). The wound bed comprised of 90% slough and 10% necrotic tissue [Figure 3a]. Three additional necrotic patches were also identified at the anterior aspect of the left leg. Signs of wound infection were present, and the patient reported experiencing severe wound-related pain.

Treatment

HydroClean® Advance (7.5cm x 7.5cm) was chosen as the primary dressing, with the treatment objectives of removing slough and necrotic tissue and managing local infection. Zetuvit® Plus Silicone Border was applied as a secondary dressing to maintain moisture balance and provide pressure relief, as the leg was immobilised in a back slab.

Results

HydroClean® Advance supported wound healing by promoting autolytic debridement, gently loosening and desloughing necrotic tissue and facilitating a cleaner wound bed, as observed at the first review, 5 days after treatment [Figure 3b].

By the second review on day 12, signs of infection, slough and necrotic tissue had significantly reduced to form a healthy granulating wound bed covering 95% of the area [Figure 3c]. Early signs of hypergranulation tissue were observed; however, this was managed using silver nitrate and light pressure to prevent further development. HydroClean® was also found to minimise dressing-related pain and trauma by preventing the dressing from adhering to the wound bed.

As the wound bed showed good progress, Zetuvit® Plus Silicone Border was introduced as the primary dressing to promote continued granulation tissue formation, support ongoing healing, provide slight pressure for local pain management, and reduce the risks of maceration and hypergranulation [Figure 3d].

Zetuvit® Plus Silicone Border was used for the next 90 days, alongside HydroClean® for the initial 12 days, contributing to the complete healing of the wound within 102 days.

Case 2. Left ischaemic ulcer with exposed tendon

Patient presentation and history

A 68-year-old female presented with an ischaemic ulcer on the outer dorsal side of her left foot. Previous treatment included hydrofiber and alginate hydrogel dressings as an outpatient in the general surgery department, with limited success. Her medical history included atrial fibrillation, hypertension, ischaemic heart disease and a recent acute ischaemic stroke. She had also undergone coronary angiography with stenting. Due to

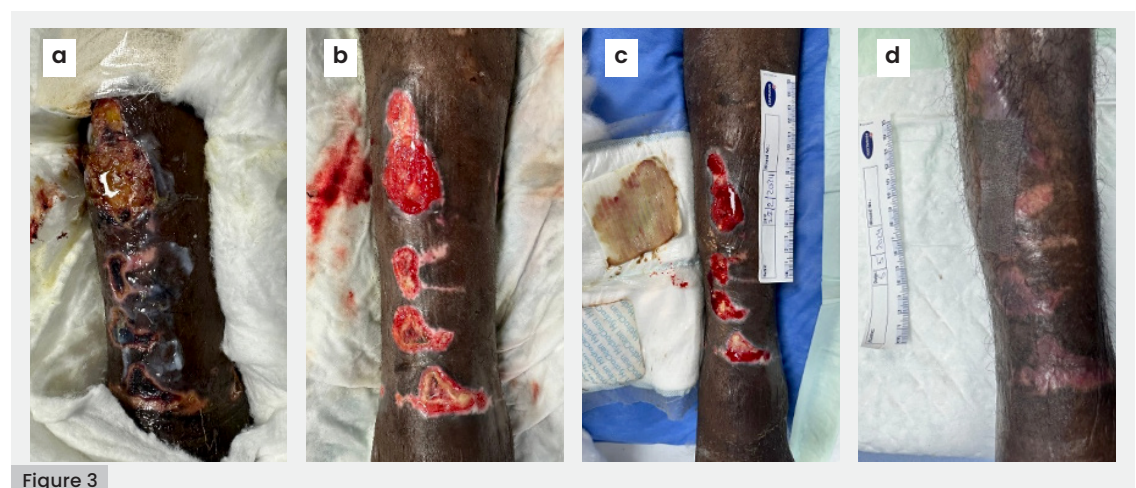


Figure 3

Figure 3. a) Wound at presentation, b) Wound at first review (day 5), c) Healthy granulating wound bed at second review (day 12), d) Wound at ninth review (day 76)

the presence of multiple necrotic wounds, she was referred to the wound care department for further evaluation and management.

Wound assessment

The wound care team assessed the left foot ulcer, which had been present for 42 days. It consisted of 100% necrotic tissue, with black eschar, macerated wound edges and signs of oedema [Figure 4a]. The wound measured 13cm (length) x 6cm (width) and had no depth. Despite a 10-day course of Cefepime 1 gm IV TID, the wound still had a foul-smelling odour, indicating ongoing infection. The patient reported mild to moderate wound-related pain.

Treatment

HydroClean® Advance was chosen as the primary dressing with the treatment objectives of facilitating autolytic debridement and removing necrotic tissue. Zetuvit® Plus Silicone Border was applied as a secondary dressing to maintain moisture balance.

Results

During the first and second reviews, HydroClean® Advance supported wound healing by promoting autolytic debridement, gently loosening and desloughing necrotic tissue, and facilitating a clean, granulating wound bed

[Figure 4b]. However, by the third review, due to the patient's comorbidities, she attended a different clinic where, based on the advice of a non-wound care specialist, her treatment plan was changed to a silver carboxymethylcellulose hydrofiber dressing [Figure 4c].

After this change in treatment plan, the patient later noticed that her wound had deteriorated and appeared necrotic again, prompting her to return to the wound care clinic [Figure 4d]. Silver depositions were found in the wound bed, and as a result, the decision was made to recommence treatment with HydroClean® Advance and a secondary dressing for fixation [Figure 4e].

By the eighth review, which included all assessments from the start of treatment, including those at the previous clinic, the wound bed appeared clean, with healthy granulating tissue [Figure 4f].

Conclusion

The gentle debridement provided by HydroClean® Advance played a crucial role in the healing process, especially considering the patient's ischaemia and health. In addition to promoting granulation tissue formation, this approach helped accelerate the healing process. Zetuvit® Plus Silicone Border was then selected as the primary dressing until complete healing.

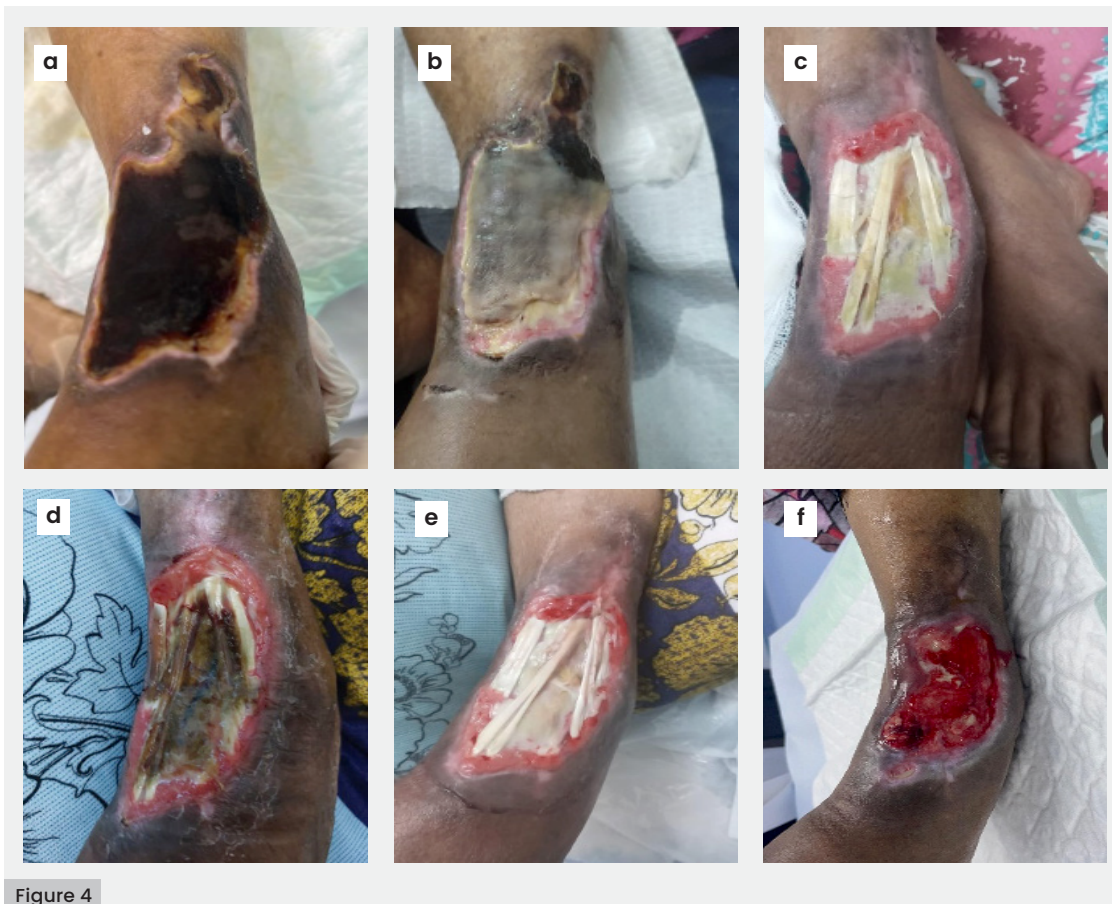

Figure 4. a) Wound at presentation, b) First review, c) Third review, d) Deterioration at fourth review with use of silver-containing dressing, e) Sixth review, f) Healthy granulating wound bed at eighth review

Case 3. Management of multiple infected carbuncles on the trunk

Patient presentation and history

A 57-year-old male presented with a 20-day history of swelling and discharge at multiple sites: the upper right abdomen, right hip and right posterior lower chest wall. His medical history included diabetes with suboptimal glycaemic control and recurrent abscess formation, which typically resolved spontaneously without the need for surgical intervention.

Wound assessment

The wound care team identified three primary wounds that had been present for 11 days:

- 1. Abdominal wound:** located on right upper quadrant of the abdomen, measuring 5cm (length) x 5cm (width) x 4cm (depth), with the wound bed comprising of 70% slough and 30% granulation tissue [Figure 5a]
- 2. Hip wound:** located on the right hip, measuring 5cm (length) x 5cm (width) x 1.8cm (depth), with the wound bed comprising of 75% granulation tissue and 25% slough [Figure 6a]
- 3. Chest wound:** located on the right posterior chest, measuring 15cm (length) x 10cm (width) x 5cm (depth), with the wound bed comprising of 75% epithelialisation tissue and 25% slough [Figure 7a].

Infection was noted in both the abdominal and hip wounds, with the patient reporting moderate to severe wound-related pain on cleansing.

The patient was admitted under the care of general surgery, where he underwent surgical management for multiple carbuncles on the right side of his trunk. Excision and debridement procedures were performed to address all affected areas. Post-surgery, an amorphous gel containing calcium alginate and multilayered silicone foam dressing were applied to the wounds on the right abdominal wall and hip, whereas negative pressure wound therapy with instillation (NPWTi) was applied to the wound on the right posterior chest. The patient was subsequently referred to the wound care department 11 days after initial presentation for further management.

Treatment

HydroClean® Advance (7.5cm x 7.5cm) was chosen as the primary dressing for the abdominal and hip wounds, with the treatment objectives of reducing slough and addressing the infection at the wound base. Zetuvit® Plus Silicone Border (10cm x 10cm) was used as

a secondary dressing to secure the primary dressing, minimise the risk of periwound maceration and manage wound exudate effectively. For the chest wound, cleansing was performed and NPWTi was continued, with dressing changes every five days.

Results

At the first review on day 7, improvements were seen in all three wounds:

- 1. Abdominal wound:** measuring 5cm (length) x 3.2cm (width) x 1.5cm (depth), with the wound bed comprising of 100% granulation tissue [Figure 5b]
- 2. Hip wound:** measuring 5cm (length) x 2cm (width) x 0.8cm (depth), with the wound bed comprised of 96% granulation tissue and 4% slough [Figure 6b]
- 3. Chest wound:** measuring 15cm (length) x 9cm (width) x 3cm (depth), with the wound bed comprised of 100% granulation tissue [Figure 7b].

At this stage, the general surgery team decided to proceed with the closure of all carbuncle wounds in the operating theatre. Following closure, treatment continued with Zetuvit® Plus Silicone Border for the abdominal and hip wounds, while a silicone foam dressing with silver was applied to the chest wound.

At the second review on day 27, the abdominal, hip and chest wounds appeared healthy, with surgical clips still in place and no signs of infection or discharge [Figure 5c and 6c]. As a result, sutures were removed, and the patient was instructed to cleanse the wound with betadine and apply Zetuvit® Plus Silicone Border every three days at home.

However, swelling was noted a day later at the left upper edge of the closed chest wound, indicating a potential subcutaneous abscess and reinfection. As a result, the chest wound was reopened to drain the abscess. Given the effectiveness of HydroClean® Advance and Zetuvit® Plus Silicone Border in managing the abdominal and hip wounds, these dressings were also applied post-operatively to the reopened chest wound.

By the third review, on day 27, the abdominal and hip wounds had healed completely without complications, following treatment with HydroClean® Advance and Zetuvit® Plus Silicone Border [Figure 5d and 6d].

Conclusion

The combined use of HydroClean® Advance and Zetuvit® Plus Silicone Border optimised WBP, infection control, slough removal and exudate management for the abdominal and hip wounds, despite the patient's persistent

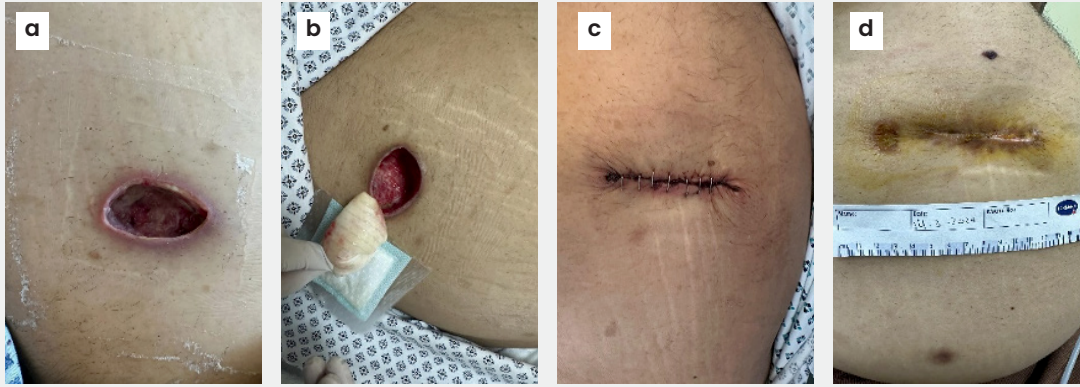


Figure 5

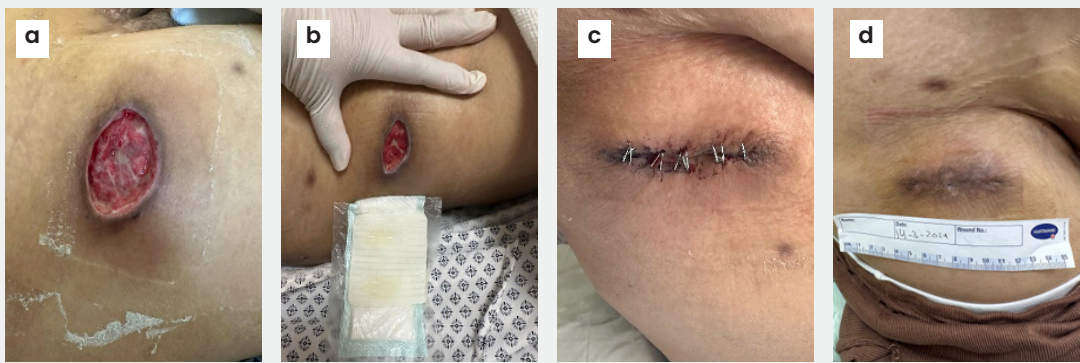


Figure 6

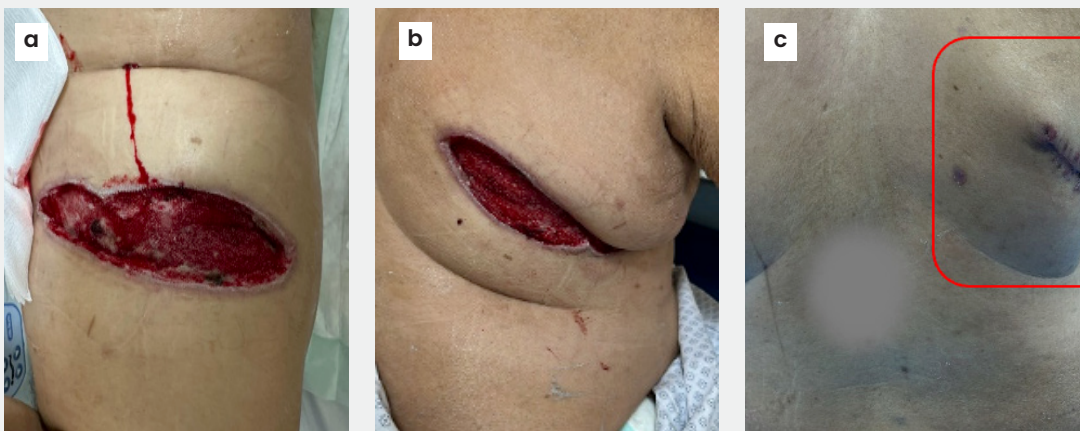


Figure 7

Figure 5. Right abdominal wound a) at presentation, b) First review, c) Second review, d) Healthy granulating wound bed at third review

Figure 6. Right hip wound a) Wound at presentation, b) First review with healthy granulating wound bed, c) Second review with sutured wound, d) Successful healing at third review

Figure 7. Right posterior chest wound. a) Wound at presentation, b) First review with healthy granulating wound bed, c) Abscess recollection at third review

poor glycaemic control. Rapid infection control and timely wound closure were critical in stabilising blood sugar levels, as infections can significantly affect glycaemic control. When introduced to the chest wound, the same treatment approach also contributed to wound healing [Figure 7c].

Discussion

The presented case studies highlight the versatility of HydroClean® and HydroClean® Advance in managing a wide variety of wound conditions. These dressings effectively remove necrotic tissue and slough by promoting autolytic debridement, optimise WBP, control

infection and regulate moisture levels, all of which are critical in transitioning chronic wounds to an acute healing phase.

Autolytic debridement uses the body's own enzymes to soften and liquefy devitalised tissue and slough, leading to their eventual detachment from the wound bed (Manna et al, 2023; Nair et al, 2024). This mechanism aids infection management by enabling bacteria contained within the necrotic tissue to be removed. Across all cases, infection was successfully resolved and a clean wound bed with healthy granulation tissue was achieved.

HydroClean® was shown to be more effective compared to silver-containing dressings, such

as the silver carboxymethylcellulose hydrofiber dressing used in case 2 (pages 44–45), which resulted in wound deterioration until HydroClean® Advance was reintroduced.

Its hydro-responsive properties help maintain optimal wound moisture levels, which is essential for healing. This was especially evident in case 3 (pages 46–48), where the combined use of HydroClean® and Zetuvit Plus Silicone Border successfully managed exudate and prevented periwound maceration. By balancing the moisture environment, HydroClean®/HydroClean® Advance helps modulate protease activity and prevents excess inflammation, creating conditions conducive to granulation and re-epithelialisation. Additionally, HydroClean® demonstrated bacterial and biofilm reduction, as evidenced in case 3, where its use contributed to successful WBP before surgery and closure, without complications, in comparison to NPWTi.

Another major benefit of HydroClean® is its non-adherent nature, which minimises trauma and pain during dressing changes. Across all cases, patients experienced reduced pain and discomfort, contributing to increased engagement with treatment and improving quality of life.

Conclusion

HRWDs such as HydroClean®/HydroClean® Advance are SAP-containing dressings, designed to regulate wound balance and provide patient-centred wound care by promoting WBP, infection control, moisture balance and patient comfort. The clinical case studies presented demonstrate the action of these dressings in overcoming critical barriers to healing, supporting antimicrobial stewardship and optimising patient care. The cases have emphasised the effectiveness of HydroClean® in transitioning wounds from being chronic to an acute state, thereby restoring a normal wound healing trajectory to facilitate the next stage of wound healing.

The second paper in this series will further explore cases 1 and 2 and explore the mechanism of action of Zeutivit® Plus Silicone Borde, highlighting its role in promoting granulation, preventing hypergranulation, and supporting re-epithelialisation. ●

References

- Atkin L, Bučko Z, Conde Montero E et al (2019) Implementing TIMERS: the race against hard-to-heal wounds. *Journal of Wound Care* 28(3a): 1–50
- Atkin L, Ousey K (2016) Wound bed preparation: a novel approach using HydroTherapy. *Br J Community Nurs* 21(12): 23–8
- Dowsett C, Ayello E (2004) TIME principles of chronic wound bed preparation and treatment. *Br J Nurs* 13(15): 16–23
- Dowsett C, Hall Y (2019) T.I.M.E to improve patient outcomes: optimising wound care through a clinical decision support tool. *Br J Nurs* 28(6): 17–21
- Goedecke F, Bühring J, Kratz A et al (2022) An observational study of wounds treated with hydro-responsive wound dressings. *Journal of Wound Care* 31(12)
- Humbert P, Faivre B, Veran Y et al (2014) Protease-modulating polyacrylate-based hydrogel stimulates wound bed preparation in venous leg ulcers – a randomized controlled trial. *J Eur Acad Dermatol Venereol* 28(12): 1742–50
- Interagency Coordinating Group on Antimicrobial Resistance (2019) No Time To Wait: Securing The Future From Drug-Resistant Infections. Report to the Secretary-General of the United Nations. Available at: <https://tinyurl.com/5c6c4dvc>
- International Wound Infection Institute (2022) Wound Infection in Clinical Practice. *Wounds International*
- Manna B, Nahirniak P, Morrison CA (2023) Wound debridement. NIH National Library of Medicine. Available at: <https://www.ncbi.nlm.nih.gov/books/NBK507882/>
- Mikosinski J, Kalogeropoulos K, Bundgaard L et al (2022) Longitudinal evaluation of biomarkers in wound fluids from venous leg ulcers and split thickness skin graft donor site wounds treated with a protease-modulating wound dressing. *Acta Derm Venereol* 102: adv00834
- Moore Z, Dowsett C, Smith G et al (2019) TIME CDST: an updated tool to address the current challenges in wound care. *J Wound Care* 28(3): 154–61
- Nair HKR, Balasubramaniam S, Frescos N et al (2024) Autolytic continuous debridement with a focus on biofilm management: Consensus document for the APAC region. *Wounds International*
- Olsson M, Järbrink K, Divakar U et al (2019) The humanistic and economic burden of chronic wounds: A systematic review. *Wound Repair Regen* 27(1): 114–25
- Ousey K, Rogers AA, Rippon MG (2016a) HydroClean plus: a new perspective to wound cleansing and debridement. *Wounds UK* 12(1): 94–104
- Ousey K, Rogers AA, Rippon MG (2016b) Hydro-responsive wound dressings simplify T.I.M.E. wound management framework. *Br J Community Nurs* 21(12):39–49
- Rippon MG, Rogers AA, Ousey K (2021) Antimicrobial stewardship strategies in wound care: evidence to support the use of dialkylcarbamoyl chloride (DACC)-coated wound dressings. *J Wound Care* 30(4): 284–96
- Rogers AA, Rippon MG (2017) Describing the rinsing, cleansing and absorbing actions of hydrated superabsorbent polyacrylate polymer dressings. *Wounds UK* 48–53
- Schultz GS, Sibbald RG, Falanga V et al (2003) Wound bed preparation: a systematic approach to wound management. *Wound Repair Regen* 11(1): 1–28
- Steripone F, Mas K, Rippon M et al (2021) The clinical impact of hydroresponsive dressings in dynamic wound healing: Part 1. *Journal of Wound Care* 30(1)
- World Union of Wound Healing Societies (2020) The role of non-medicated dressings for the management of wound infection. London: *Wounds International*
- Wounds International (2023) Wound balance: achieving wound healing with confidence. *Wounds International*